

# Accepted Manuscript

Retinal layers in Parkinson's disease: A meta-analysis of spectral-domain optical coherence tomography studies

Asterios Chrysou, Nomdo M. Jansonius, Teus van Laar



PII: S1353-8020(19)30218-4

DOI: <https://doi.org/10.1016/j.parkreldis.2019.04.023>

Reference: PRD 4019

To appear in: *Parkinsonism and Related Disorders*

Received Date: 5 April 2018

Revised Date: 15 March 2019

Accepted Date: 29 April 2019

Please cite this article as: Chrysou A, Jansonius NM, van Laar T, Retinal layers in Parkinson's disease: A meta-analysis of spectral-domain optical coherence tomography studies, *Parkinsonism and Related Disorders* (2019), doi: <https://doi.org/10.1016/j.parkreldis.2019.04.023>.

This is a PDF file of an unedited manuscript that has been accepted for publication. As a service to our customers we are providing this early version of the manuscript. The manuscript will undergo copyediting, typesetting, and review of the resulting proof before it is published in its final form. Please note that during the production process errors may be discovered which could affect the content, and all legal disclaimers that apply to the journal pertain.

## **Retinal layers in Parkinson's disease: a meta-analysis of spectral-domain optical coherence tomography studies**

Asterios Chrysou MSc <sup>1\*</sup>, Nomdo M. Jansonius MD, PhD <sup>2</sup>, Teus van Laar MD, PhD <sup>1</sup>

1. Department of Neurology, University of Groningen, University Medical Center Groningen, Groningen, the Netherlands
2. Department of Ophthalmology, University of Groningen, University Medical Center Groningen, Groningen, the Netherlands

### Correspondence:

Asterios Chrysou\*, Dept. of Neurology, University Medical Center Groningen, P.O.Box 30.001, 9700 RB Groningen, Netherlands. Email: a.chrysou@rug.nl Phone: +31 50 361 2401

Prof.dr. Nomdo M. Jansonius, Dept. of Ophthalmology, University Medical Center Groningen, P.O.Box 30.001, 9700 RB Groningen, Netherlands. Email: n.m.jansonius@umcg.nl

Prof.dr. Teus van Laar, Dept. of Neurology, University Medical Center Groningen, P.O.Box 30.001, 9700 RB Groningen, Netherlands. Email: t.van.laar@umcg.nl

Declarations of interest: None.

Funding: This study was funded by the European Union (EU) Horizon 2020 grant No 661883 European Glaucoma Research Training Program (EGRET).

KEYWORDS: Parkinson, Retina, Optical Coherence Tomography, RNFL, Retinal nerve fiber layer.

## Abstract

**Background** Patients with Parkinson's disease experience visual symptoms, partially originating from retinal changes. Since 2011, multiple case-control studies using spectral-domain OCT, which allows for studying individual retinal layers, have been published. The aim of this study was to substantiate the occurrence, extent, and location of retinal degeneration in Parkinson's by meta-analysis.

**Methods** Spectral-domain OCT case-control data were collected by performing a search in PubMed and Embase with terms: "optical coherence tomography" and "parkinson", up to November 5th 2018. Studies with fewer than 10 patients or controls were excluded. We performed a random effects meta-analysis. Heterogeneity was evaluated with  $I^2$  statistics; publication bias with Egger's and Begg's tests.

**Results** Out of 77 identified studies, 36 were included, totaling 1916 patients and 2006 controls. A significant thinning of the peripapillary retinal nerve fiber layer ( $d = -0.42$ ; 95% confidence interval  $-0.54$  to  $-0.29$ ) and the combined ganglion cell and inner plexiform layers ( $d = -0.40$ ;  $-0.72$ , to  $-0.07$ ) was found. The inner nuclear layer and outer plexiform layer did not show significant changes. Heterogeneity ranged from 3 to 92%; no publication bias was found.

**Conclusions** Parkinson's patients show significant thinning of the inner retinal layers, resembling changes found in glaucoma and other neurodegenerative diseases like Alzheimer's. Study of different cell layers in-vivo is possible by moving from time-to spectral domain OCT. Retinal degeneration may be affiliated with neurodegenerative pathology overall, and could serve as a biomarker in neurodegenerative disorders. Longitudinal research including clinical correlations is needed to determine usefulness in Parkinson's disease.

## Introduction

Parkinson's disease is a progressive neurodegenerative disorder. Besides the motor symptoms, Parkinson's disease may present with a variety of non-motor symptoms, including cognitive deficits [1,2], depression, REM-sleep behavior disorder, dementia [3], and also visual complaints and visual hallucinations [4–8]. As an extension of the central nervous system [9,10], the retina has drawn interest as a window into pathological processes in the brain. Multiple OCT studies have investigated the retina and report retinal nerve fiber layer (RNFL) thinning and ganglion cell layer (GCL) abnormalities in Parkinson's disease [11–47], Alzheimer's disease, and multiple sclerosis [48,49]. However, the effects are subtle, mostly based on cross-sectional cohorts, with varying methodologies, resulting in very heterogeneous outcomes. Several studies have compared RNFL and GCL abnormalities in Parkinson's [35,43] and Alzheimer's [48] with glaucoma. As reported in more detail in the Discussion section, the thinning of the concerning retinal layers seems more pronounced in glaucoma than in Parkinson's; the RNFL thinning topography, however, seems to mimic that of glaucoma, with a relative sparing of the fibres entering the optic nerve head nasally.

Optical coherence tomography (OCT) [50], introduced in 1991, is a noninvasive technique that can be used for the in-vivo imaging of tissue. Light from a low-coherent light source is split into two bundles; one bundle is reflected by the tissue, the other bundle by a reference mirror. Once reflected and brought together again, interference occurs. Tissue properties can be derived from the interference pattern and cell layers can be discriminated if their optical properties differ. In time-domain OCT (TD-OCT), the reference mirror is moved back and forth in order to get depth information from the tissue; in spectral-domain OCT (SD-OCT), different colors in the reflected light are analyzed in a sophisticated way, allowing for the retrieval of depth information without the need of a moving reference mirror. As a result, SD-OCT is faster and has a better signal-to-noise ratio [51,52]. With TD-OCT, only the (high-reflective) retinal nerve fiber layer (RNFL) and the retinal pigment epithelium (RPE) can be visualized (the distance between these layers represents the total retinal thickness) SD-OCT, however, is able to assess all retinal layers separately.

In 2014, an important meta-analysis on OCT in Parkinson's disease was published [53]. This meta-analysis also reported results from TD-OCT. However, since then, many studies using SD-OCT were published. Given the better signal-to-noise ratio of SD-OCT and the ability to assess all individual layers, we performed an updated meta-analysis, incorporating these recent SD-OCT studies, in order to see if more detailed results could be obtained of the retinal degeneration in Parkinson's, and how these data compare to the current findings in other neurodegenerative diseases and glaucoma.

## Methods

### Data collection

A literature search was conducted in PubMed and Embase. The search term for PubMed was: "parkinson[All Fields] AND ("tomography, optical coherence"[MeSH Terms] OR ("tomography"[All Fields] AND "optical"[All Fields] AND "coherence"[All Fields]) OR "optical coherence tomography"[All Fields] OR ("optical"[All Fields] AND "coherence"[All Fields] AND "tomography"[All Fields]))". The search term for Embase was: "('parkinson disease'/exp OR 'parkinson disease') AND ('optical'/exp OR optical) AND ('coherence'/exp OR coherence) AND ('tomography'/exp OR tomography)". The search and data extraction was performed by the first author (AC). The full text of potentially eligible studies was analyzed to check for in- and exclusion criteria. In addition, the reference list from all identified studies was checked. Authors were approached for missing, ambiguously presented, or unpublished data, and for corrections. PRISMA [54] guidelines were followed. Publications were included if published before November 5th 2018.

### Inclusion and exclusion criteria

Studies were included if they (1) reported on retinal layer thicknesses assessed with SD-OCT, (2) had a case-control design, (3) included as least 10 Parkinson's patients and 10 controls, (4) reported the thickness of at least one retinal layer in the macular area or the peripapillary retinal nerve fiber layer (pRNFL), and (5) reported the mean and standard deviation in  $\mu\text{m}$ , or allowed

for the calculation of it from the data presented in the article. We excluded studies published in a non-English language and studies published before 2006, when the Federal Drug Administration approved SD-OCT [55]. We checked for duplicate analysis and, if present, we only included the most recent publication. The SD-OCT devices included in the meta-analysis were Cirrus HD-OCT (Carl Zeiss Meditec, Dublin, California, USA), SOCT Copernicus (Optopol, Zawiercie, Poland), RT-Vue 100 (OptoVue, Fremont, California, USA), Spectralis (Heidelberg Engineering, Heidelberg, Germany), and Topcon 3D OCT (Topcon, Itabashi-ku, Tokyo, Japan).

### **Statistical analysis**

The number of Parkinson's patients, healthy subjects (controls), mean thickness values in  $\mu\text{m}$  and standard deviations were entered into the meta-essentials workbook function three comparing differences between independent groups and continuous data [56]. We calculated, per cell layer, the Cohen's  $d$  effect size of each study and subsequently the corresponding pooled effect size and 95% CI, using a random effects model. The random effects model was chosen because we expected a significant heterogeneity (different SD-OCT devices, different disease stages, etc.). Heterogeneity was evaluated using the  $I^2$  statistic.  $I^2$  is the percentage of the total variation across the studies that is due to heterogeneity. Values up to 25%, 25-49%, 50-74%, and 75% and above are considered no, low, moderate, and high heterogeneity, respectively. We performed a sensitivity analysis to evaluate the contribution of each individual study to the heterogeneity by sequentially leaving out one study and reanalyzing the pooled estimate for the remaining studies. Publication bias was assessed with Egger's regression asymmetry test and Begg's adjusted rank correlation test. In addition to the mean layer thicknesses, we also analyzed the pRNFL for four (superior, temporal, inferior, nasal) individual sectors and the overall thickness of the macular area for nine different regions of interest (ROIs) as defined by the Early Treatment of Diabetic Retinopathy Study (ETDRS grid) [57]. For the sector wise and ROI wise analysis, we only included studies that reported on all sectors/ROIs.

### **Results**

Overall 36 studies were included according our criteria. (Fig. 1). Table 1 presents the characteristics of the included population. One study [21] was included twice in the meta-analysis, having reported two independent samples. The studies included originate from 2009-2018. The numeration assigned to the 36 included studies in the tables corresponds to reference numbers 12-47.

Table 2 presents the data underlying the random effects meta-analyses. A significant thinning was found for the pRNFL and the ganglion cell layer-inner plexiform layer (GCL-IPL); none of the outer retinal layers showed any significant thinning. Figs. 2 and 3 show the forest plots for the pRNFL (Fig. 2) and the GCL-IPL (Fig. 3). The pooled Cohen's d values across all studies were: pRNFL ( $d = -0.42$ ; 95% confidence interval  $-0.54$  to  $-0.29$ ), GCL-IPL ( $d = -0.40$ ;  $-0.72$  to  $-0.07$ ), inner nuclear layer (INL) ( $d = -0.01$ ;  $-1.03$  to  $1.01$ ) and outer plexiform layer (OPL) ( $d = 0.11$ ;  $-0.25$  to  $0.47$ ). As can be seen in Table 2, two studies reported on the outer nuclear layer (ONL) [27,46], however they were not meta-analyzed due to reporting thicknesses on different ROIs. One study reported on the combined IRLs (RNFL, GCL, and IPL) and ORLs (INL to retinal pigment epithelium) [12], and one on the retinal pigment epithelium (RPE).

Some studies provided data regarding clinical characteristics. The most widely available clinical data were age and disease duration. There was no significant correlation between the pRNFL weighted mean difference (Parkinson's versus control) and mean age (Kendall's tau-b  $0.14$ ; 95% CI  $-0.13$  to  $0.41$ ,  $P=0.26$ ) or the pRNFL weighted mean difference (Parkinson's versus control) and disease duration ( $0.23$ ;  $0.01$  to  $0.45$ ,  $P=0.06$ ) in the studies listed in Table 2a. After excluding the studies done at medication off state, there was no significant correlation between the pRNFL weighted mean difference (Parkinson's versus control) and UPDRS III (Kendall's tau-b  $0.29$ ; 95% CI  $-0.50$  to  $1.09$ ,  $P=0.36$ ), UPDRS total ( $0.40$ ;  $-0.40$  to  $1.20$ ,  $P=0.48$ ), and Hoehn & Yahr (HY) ( $0.22$ ;  $-0.24$  to  $0.70$ ,  $P=0.29$ ). The number of studies done at medication off state was too small to calculate meaningful correlations (Table 1).

Regarding heterogeneity, the  $I^2$  was 64% for the pRNFL, 75% for GCL-IPL, 82% for INL, and 38% for OPL. The sensitivity analyses did not show a single study casting a significant undue weight in increasing heterogeneity. Also no significant publication bias was found in the

statistical evaluation of the funnel plots (Egger regression: pRNFL P=0.11, GCL-IPL P=0.98, INL P=0.42, OPL P=0.08; Begg and Mazumdar rank correlation test: pRNFL P=0.15, GCL-IPL P=0.93, INL P=0.32, OPL P=1.0).

Table 3 shows the summarized meta-analysis results for the overall (all layers together) retinal thickness in the macular area, for various ROIs. Fig. 4 gives the corresponding summary forest plot. The retina appeared to be clearly thinner in Parkinson's patients compared to controls; this was the least pronounced in the fovea.

Finally, Table 4 presents the summarized meta-analysis results for the sector specific layer thicknesses of the pRNFL. Fig. 5 shows the corresponding summary forest plot. A clear thinning was present in all sectors, except for the nasal sector.

Several papers reported measures of clinical functioning (Table 1) like the Unified Parkinson's Disease Rating Scale (UPDRS), Mini-Mental State Examination (MMSE) and the Hoehn & Yahr stage. We summarized the clinical details in Table 1. These data were collected at different states of the Parkinson's patients and thus showed substantial heterogeneity. Therefore we did not meta-analyze these data.

## Discussion

This meta-analysis shows that Parkinson's patients have significantly thinner retinas compared to age- and gender-matched controls. Especially the inner retinal layers are affected, consisting of the RNFL and GCL-IPL. The RNFL around the optic nerve head is affected mainly inferiorly, superiorly, and temporally, with an apparent sparing of the nasal sector.

### Comparison with previous studies on OCT in Parkinson's disease

Our meta-analysis confirms previous data of Yu *et al.* [53]. The main result from their study was that the mean pRNFL was significantly thinner in 644 Parkinson's eyes versus 604 control eyes (weighted mean difference -5.8  $\mu\text{m}$ , 95% CI -9.0 to -2.5), with the largest effect in the inferior



quadrant ( $-7.6 \mu\text{m}$ ) and the smallest effect in the nasal quadrant ( $-3.1 \mu\text{m}$ ). We showed a significantly reduced mean pRNFL ( $-4.2 \mu\text{m}$ ), with a significant thinning in all four pRNFL sectors, with the largest effect in the inferior quadrant ( $-6.0 \mu\text{m}$ ) and the smallest effect in the nasal quadrant ( $-1.7 \mu\text{m}$ ; Table 4, Fig. 5). Five of the thirteen studies [58–62] Yu *et al.* meta-analyzed used TD-OCT; these too reported significant pRNFL thinning (on average  $-5.5 \mu\text{m}$ ), in all sectors (superior, inferior, nasal, temporal). We extended the previous work by adding 30 SD-OCT studies and analyzing all retinal cell layers including the pRNFL, GCL-IPL, INL, OPL, ONL as well as the overall retinal thickness in the macular region, divided in nine ROIs, which gives a more detailed picture of the findings in Parkinson's patients.

### **Limitations and strengths of this meta-analysis**

Most papers did not report on the ethnicity of their participants. Therefore we were not able to stratify our results by ethnic background. Another limitation involves the lack of uniformity and availability of the reported data. Many studies used different names and divisions of the retinal cell layers, and different clinical screening instruments. A strength of our analysis is the inclusion of a range of countries and ethnic backgrounds, and the diversity of SD-OCT machines used. Because the sensitivity analysis did not indicate any obvious study or device-related bias, this reinforces the validity of the reported main effect on retinal thickness. All studies excluded participants with pre-existing retinal disorders as possible confounders, especially glaucoma and ocular hypertension. This is a limitation as glaucoma and Parkinson's may share a common pathophysiology [63–66]. Data regarding the most affected side of the included Parkinson's patients, compared with SD-OCT scans of both eyes, unfortunately was not sufficient for a meta-analysis. Finally, a drawback of this meta-analysis is the fact that almost all studies were cross-sectional, so no causal relationships could be established based on these data. Future SD-OCT trials therefore should focus on longitudinal data collection.

### **Comparison with other neurodegenerative disorders and glaucoma**

Retinal degeneration has been identified in multiple diseases and neurodegenerative disorders [10,48,49,67,68]. This brings-up the question if the changes found in Parkinson's patients are disease-specific or not.

First of all the most recent OCT case-control meta-analysis in glaucoma patients [69], including both TD-OCT and SD-OCT studies, showed a similar pattern compared to our meta-analysis in Parkinson's patients, with relative sparing of the nasal sector of the pRNFL. This might indicate a common underlying pathophysiology, with a more progressive variant indicating glaucoma and a milder variant related to Parkinson's patients [38,44]. In Alzheimer's disease, slightly different findings were reported, existing of, the most recent OCT case control meta-analysis [70], including both TD-OCT and SD-OCT studies, reported a significant thinning in all (superior, inferior, nasal and temporal) quadrants of the pRNFL. Significant effects were also found for the macular thickness; including the outer ring, the inner ring, and the fovea. The smallest effect size was reported in the fovea, which agrees with our findings.

Another argument for a possible interplay between glaucoma and Parkinson's can be found in the incidence figures of glaucoma in Parkinson's and vice versa. A 10-year retrospective study conducted in 2017 [66], reported an increased incidence of Parkinson's in patients with primary open angle glaucoma, reporting a hazard ratio of 1.28 (95% CI; 1.05 to 1.46) in comparison to healthy controls. Also an increased incidence of glaucomatous findings in Parkinson's disease patients (23.7%) [63], and a higher incidence of glaucoma (16.3% vs 6.6% in healthy controls) was reported [71]. Finally some basic pathological mechanisms show similarities in glaucoma, Parkinson's and Alzheimer's. The first one is the presence of microglial activation, as a marker of neuroinflammation, which has been reported in glaucoma as well as Parkinson's and Alzheimer's. Another common factor between glaucoma and Parkinson's/Alzheimer's is the deposition of proteins in the retina, like beta-amyloid, alpha-synuclein and phosphorylated tau, which suggests shared neurodegenerative processes [65].

### **Clinical implications**

At this moment it is unclear what the OCT findings in Parkinson's patients do mean with respect to the progression and diagnosis of Parkinson's. The cross-sectional studies are not useful to draw conclusions with respect to causality or the risk on Parkinson's. However, the current OCT data show some interesting similarities in retinal thinning between glaucoma and/or Alzheimer's. Therefore OCT could become an interesting diagnostic tool because of its ease of use. The existing cross-sectional studies are only useful to look at correlations between OCT and clinical markers. One study showed that foveal thickness was inversely correlated with UPDRS (total UPDRS and motor scores) [26]. Another study [38] presented multiple inverse correlations of macular thickness (inner superior, inner nasal, inner inferior, inner temporal, outer nasal, outer inferior, and outer temporal region) with disease severity, expressed by the Hoehn and Yahr stage. Disease duration was especially correlated with the thickness of the nasal RNFL quadrant. These correlations between retinal thickness and severity were confirmed by several other studies [12,20,22,23,26,39].

### **Future directions of research**

To get a better insight in the relationship between retinal changes in glaucoma and neurodegenerative diseases like and Alzheimer's, it is crucial to set-up and analyze longitudinal cohorts on glaucoma and or Alzheimer's, using SD-OCT, with extensive monitoring of the clinical features of these diseases. Thereabove, it would be very important to analyze cohorts of prodromal patients, in order to establish the causality between symptoms and retinal changes.

### **Conclusion**

In conclusion, based on the current SD-OCT data, Parkinson's patients do show thinning of the inner retinal layers, which resembles the retinal patterns in glaucoma patients and different neurodegenerative diseases, like Alzheimer's disease. The question remains if this retinal thinning seen with SD-OCT could play a role as a possible biomarker. To solve that question, in depth longitudinal analyses are needed, with detailed clinical descriptions of the separate syndromes, which should dictate future research on this topic.

**Funding**

This study was funded by the European Union (EU) Horizon 2020 grant No 661883, European Glaucoma Research Training Program (EGRET). Funders were not involved in the study design, collection, analysis, interpretation of data, writing or decision to publish.

**Author roles**

AC: research project (conception, organization, execution); statistical analysis (design, execution); manuscript preparation (writing of the first and final draft).

NJ: research project (conception, organization); statistical analysis (design); manuscript preparation (review and critique).

TvL: research project (conception, organization); statistical analysis (design); manuscript preparation (review and critique).

## References

- [1] G.S. Watson, J.B. Leverenz, Profile of cognitive impairment in Parkinson's disease, *Brain Pathol.* 20 (2010) 640–645. doi:10.1111/J.1750-3639.2010.00373.X.
- [2] S.J. Getz, B. Levin, Cognitive and neuropsychiatric features of early Parkinson's disease, *Arch. Clin. Neuropsychol.* 32 (2017) 769–785. doi:10.1093/ARCLIN/ACX091.
- [3] K.-Y. Kwon, S.H. Kang, M. Kim, H.M. Lee, J.W. Jang, J.Y. Kim, S.-M. Lee, S.-B. Koh, Nonmotor symptoms and cognitive decline in de novo Parkinson's disease, *Can. J. Neurol. Sci.* 41 (2014) 597–602. doi:10.1017/CJN.2014.3.
- [4] R.L. Rodnitzky, Visual dysfunction in Parkinson's disease., *Clin. Neurosci. N. Y.* NY. 5 (1998) 102–106.
- [5] R.S. Weil, A.E. Schrag, J.D. Warren, S.J. Crutch, A.J. Lees, H.R. Morris, Visual dysfunction in Parkinson's disease, *Brain.* 139 (2016) 2827–2843. doi:10.1093/BRAIN/AWW175.
- [6] M.S. Ekker, S. Janssen, K. Seppi, W. Poewe, N.M. de Vries, T. Theelen, J. Nonnekes, B.R. Bloem, Ocular and visual disorders in Parkinson's disease: Common but frequently overlooked, *Parkinsonism Relat. Disord.* 40 (2017) 1–10. doi:10.1016/J.PARKRELDIS.2017.02.014.
- [7] F. Bernardin, R. Schwan, L. Lalanne, F. Ligier, K. Angioi-Duprez, T. Schwitzer, V. Laprevote, The role of the retina in visual hallucinations: A review of the literature and implications for psychosis, *Neuropsychologia.* 99 (2017) 128–138. doi:10.1016/J.NEUROPSYCHOLOGIA.2017.03.002.
- [8] N.K. Archibald, M.P. Clarke, U.P. Mosimann, D.J. Burn, The retina in Parkinson's disease, *Brain.* 132 (2009) 1128–1145. doi:10.1093/BRAIN/AWP068.
- [9] A. London, I. Benhar, M. Schwartz, The retina as a window to the brain—from eye research to CNS disorders, *Nat. Rev. Neurol.* 9 (2013) 44–53. doi:10.1038/NRNEUROL.2012.227.
- [10] S. Gupta, R. Zivadinov, M. Ramanathan, B. Weinstock-Guttman, Optical coherence tomography and neurodegeneration: are eyes the windows to the brain?, *Expert Rev. Neurother.* 16 (2016) 765–775. doi:10.1080/14737175.2016.1180978.
- [11] R. Inzelberg, J.A. Ramirez, P. Nisipeanu, A. Ophir, Retinal nerve fiber layer thinning in Parkinson disease, *Vision Res.* 44 (2004) 2793–2797. doi:10.1016/J.VISRES.2004.06.009.

- [12] M.E. Hajee, Inner Retinal Layer Thinning in Parkinson Disease, *Arch. Ophthalmol.* 127 (2009) 737. doi:10.1001/ARCHOPHTHALMOL.2009.106.
- [13] E. Garcia-Martin, M. Satue, I. Fuertes, S. Otin, R. Alarcia, R. Herrero, M.P. Bambo, J. Fernandez, L.E. Pablo, Ability and Reproducibility of Fourier-Domain Optical Coherence Tomography to Detect Retinal Nerve Fiber Layer Atrophy in Parkinson's Disease, *Ophthalmology.* 119 (2012) 2161–2167. doi:10.1016/j.ophtha.2012.05.003.
- [14] P. Albrecht, A.-K. Müller, M. Südmeyer, S. Ferrea, M. Ringelstein, E. Cohn, O. Aktas, T. Dietlein, A. Lappas, A. Foerster, H.-P. Hartung, A. Schnitzler, A. Methner, Optical Coherence Tomography in Parkinsonian Syndromes, *PLoS ONE.* 7 (2012) e34891. doi:10.1371/JOURNAL.PONE.0034891.
- [15] M. Satue, E. Garcia-Martin, I. Fuertes, S. Otin, R. Alarcia, R. Herrero, M.P. Bambo, L.E. Pablo, F.J. Fernandez, Use of Fourier-domain OCT to detect retinal nerve fiber layer degeneration in Parkinson's disease patients, *Eye.* 27 (2013) 507–514. doi:10.1038/EYE.2013.4.
- [16] M. Rohani, A.S. Langroodi, S. Ghourchian, K.G. Falavarjani, R. SoUdi, G. Shahidi, Retinal nerve changes in patients with tremor dominant and akinetic rigid Parkinson's disease, *Neurol. Sci.* 34 (2013) 689–693. doi:10.1007/S10072-012-1125-7.
- [17] S. Kirbas, K. Turkyilmaz, A. Tufekci, M. Durmus, Retinal Nerve Fiber Layer Thickness in Parkinson Disease:, *J. Neuroophthalmol.* 33 (2013) 62–65. doi:10.1097/WNO.0B013E3182701745.
- [18] A. Sen, B. Tugcu, C. Coskun, C. Ekinci, S.A. Nacaroglu, Effects of Levodopa on Retina in Parkinson Disease, *Eur. J. Ophthalmol.* 24 (2014) 114–119. doi:10.5301/EJO.5000338.
- [19] E. Garcia-Martin, J.M. Larrosa, V. Polo, M. Satue, M.L. Marques, R. Alarcia, M. Seral, I. Fuertes, S. Otin, L.E. Pablo, Distribution of Retinal Layer Atrophy in Patients With Parkinson Disease and Association With Disease Severity and Duration, *Am. J. Ophthalmol.* 157 (2014) 470-478.e2. doi:10.1016/J.AJO.2013.09.028.
- [20] E. Garcia-Martin, D. Rodriguez-Mena, M. Satue, C. Almarcegui, I. Dolz, R. Alarcia, M. Seral, V. Polo, J.M. Larrosa, L.E. Pablo, Electrophysiology and Optical Coherence Tomography to Evaluate Parkinson Disease Severity, *Investig. Ophthalmology Vis. Sci.* 55 (2014) 696. doi:10.1167/IOVS.13-13062.
- [21] E. Garcia-Martin, M. Satue, S. Otin, I. Fuertes, R. Alarcia, J.M. Larrosa, V. Polo, L.E.

- Pablo, RETINA MEASUREMENTS FOR DIAGNOSIS OF PARKINSON DISEASE:, *Retina*. 34 (2014) 971–980. doi:10.1097/IAE.000000000000028.
- [22] E.S. Sari, R. Koc, A. Yazici, G. Sahin, S.S. Ermis, Ganglion Cell–Inner Plexiform Layer Thickness in Patients With Parkinson Disease and Association With Disease Severity and Duration:, *J. Neuroophthalmol.* (2014) 1. doi:10.1097/WNO.0000000000000203.
- [23] H.A. Bayhan, S. Aslan Bayhan, N. Tanik, C. Gürdal, The Association of Spectral-Domain Optical Coherence Tomography Determined Ganglion Cell Complex Parameters and Disease Severity in Parkinson’s Disease, *Curr. Eye Res.* 39 (2014) 1117–1122. doi:10.3109/02713683.2014.894080.
- [24] J.-Y. Lee, J.M. Kim, J. Ahn, H.-J. Kim, B.S. Jeon, T.W. Kim, Retinal nerve fiber layer thickness and visual hallucinations in Parkinson’s Disease: Retina and Visual Hallucination in PD, *Mov. Disord.* 29 (2014) 61–67. doi:10.1002/MDS.25543.
- [25] L.B. Quagliato, C. Domingues, E.M.A.B. Quagliato, E.B. de Abreu, N. Kara-Junior, Applications of visual evoked potentials and Fourier-domain optical coherence tomography in Parkinson’s disease: a controlled study, *Arq. Bras. Oftalmol.* 77 (2014). doi:10.5935/0004-2749.20140061.
- [26] M. Satue, M. Seral, S. Otin, R. Alarcia, R. Herrero, M.P. Bambo, M.I. Fuertes, L.E. Pablo, E. Garcia-Martin, Retinal thinning and correlation with functional disability in patients with Parkinson’s disease, *Br. J. Ophthalmol.* 98 (2014) 350–355. doi:10.1136/BJOPHTHALMOL-2013-304152.
- [27] M. Schneider, H.-P. Müller, F. Lauda, H. Tumani, A.C. Ludolph, J. Kassubek, E.H. Pinkhardt, Retinal single-layer analysis in Parkinsonian syndromes: an optical coherence tomography study, *J. Neural Transm.* 121 (2014) 41–47. doi:10.1007/S00702-013-1072-3.
- [28] N.M. Roth, S. Saidha, H. Zimmermann, A.U. Brandt, J. Isensee, A. Benkhellouf-Rutkowska, M. Dornauer, A.A. Kühn, T. Müller, P.A. Calabresi, F. Paul, Photoreceptor layer thinning in idiopathic Parkinson’s disease: Photoreceptors in Parkinson’s Disease, *Mov. Disord.* 29 (2014) 1163–1170. doi:10.1002/MDS.25896.
- [29] B. Stemplewitz, M. Keserü, D. Bittersohl, C. Buhmann, C. Skevas, G. Richard, A. Hassenstein, Scanning laser polarimetry and spectral domain optical coherence tomography for the detection of retinal changes in Parkinson’s disease, *Acta Ophthalmol. (Copenh.)*. 93 (2015) e672–e677. doi:10.1111/AOS.12764.

- [30] D. Bittersohl, B. Stemplewitz, M. Keserü, C. Buhmann, G. Richard, A. Hassenstein, Detection of retinal changes in idiopathic Parkinson's disease using high-resolution optical coherence tomography and heidelberg retina tomography, *Acta Ophthalmol. (Copenh.)*. 93 (2015) e578–e584. doi:10.1111/AOS.12757.
- [31] M. Kaur, R. Saxena, D. Singh, M. Behari, P. Sharma, V. Menon, Correlation Between Structural and Functional Retinal Changes in Parkinson Disease:, *J. Neuroophthalmol.* 35 (2015) 254–258. doi:10.1097/WNO.0000000000000240.
- [32] P. Mailankody, R. Battu, A. Khanna, A. Lenka, R. Yadav, P.K. Pal, Optical coherence tomography as a tool to evaluate retinal changes in Parkinson's disease, *Parkinsonism Relat. Disord.* 21 (2015) 1164–1169. doi:10.1016/J.PARKRELDIS.2015.08.002.
- [33] A. Pilat, R.J. McLean, F.A. Proudlock, G.D.E. Maconachie, V. Sheth, Y.A. Rajabally, I. Gottlob, In Vivo Morphology of the Optic Nerve and Retina in Patients With Parkinson's Disease, *Investig. Ophthalmology Vis. Sci.* 57 (2016) 4420. doi:10.1167/IOVS.16-20020.
- [34] J.A. Pillai, R. Bermel, A. Bonner-Jackson, A. Rae-Grant, H. Fernandez, J. Bena, S.E. Jones, J.P. Ehlers, J.B. Leverenz, Retinal Nerve Fiber Layer Thinning in Alzheimer's Disease: A Case–Control Study in Comparison to Normal Aging, Parkinson's Disease, and Non-Alzheimer's Dementia, *Am. J. Alzheimers Dis. Dementiasr.* 31 (2016) 430–436. doi:10.1177/1533317515628053.
- [35] M. Eraslan, S.Y. Balci, E. Cerman, A. Temel, D. Suer, N.T. Elmaci, Comparison of Optical Coherence Tomography Findings in Patients With Primary Open-angle Glaucoma and Parkinson Disease:, *J. Glaucoma.* 25 (2016) e639–e646. doi:10.1097/IJG.0000000000000239.
- [36] T. Ucak, A. Alagoz, B. Cakir, E. Celik, E. Bozkurt, G. Alagoz, Analysis of the retinal nerve fiber and ganglion cell – Inner plexiform layer by optical coherence tomography in Parkinson's patients, *Parkinsonism Relat. Disord.* 31 (2016) 59–64. doi:10.1016/j.parkreldis.2016.07.004.
- [37] V. Polo, M. Satue, M.J. Rodrigo, S. Otin, R. Alarcia, M.P. Bambo, M.I. Fuertes, J.M. Larrosa, L.E. Pablo, E. Garcia-Martin, Visual dysfunction and its correlation with retinal changes in patients with Parkinson's disease: an observational cross-sectional study, *BMJ Open.* 6 (2016) e009658. doi:10.1136/BMJOPEN-2015-009658.
- [38] M. Satue, M.J. Rodrigo, J. Obis, E. Vilades, H. Gracia, S. Otin, M.I. Fuertes, R. Alarcia,



- J.A. Crespo, V. Polo, Evaluation of progressive visual dysfunction and retinal degeneration in patients with Parkinson's disease, *Invest. Ophthalmol. Vis. Sci.* 58 (2017) 1151–1157. doi:10.1167/IOVS.16-20460.
- [39] D. Gulmez Sevim, M. Unlu, M. Gultekin, C. Karaca, M. Mirza, G.E. Mirza, Evaluation of Retinal Changes in Progressive Supranuclear Palsy and Parkinson Disease, *J. Neuroophthalmol.* 38 (2018) 151–155. doi:10.1097/WNO.0000000000000591.
- [40] D. Gulmez Sevim, M. Unlu, S. Sonmez, M. Gultekin, C. Karaca, A. Ozturk Oner, Retinal vessel diameter obtained by optical coherence tomography is spared in Parkinson's disease, *Int. Ophthalmol.* (2018). doi:10.1007/S10792-018-0873-7.
- [41] F. Visser, K.A. Vermeer, B. Ghafaryasl, A.M.M. Vlaar, V. Apostolov, J. van Hellenberg Hubar, H.C. Weinstein, J.F. de Boer, H.W. Berendse, In vivo exploration of retinal nerve fiber layer morphology in Parkinson's disease patients, *J. Neural Transm.* 125 (2018) 931–936. doi:10.1007/S00702-018-1872-6.
- [42] J. Huang, Y. Li, J. Xiao, Q. Zhang, G. Xu, G. Wu, T. Liu, W. Luo, Combination of Multifocal Electroretinogram and Spectral-Domain OCT Can Increase Diagnostic Efficacy of Parkinson's Disease, *Park. Dis.* 2018 (2018) 1–7. doi:10.1155/2018/4163239.
- [43] J. Matlach, M. Wagner, U. Malzahn, I. Schmidtman, F. Steigerwald, T. Musacchio, J. Volkmann, F. Grehn, W. Göbel, S. Klebe, Retinal changes in Parkinson's disease and glaucoma, *Parkinsonism Relat. Disord.* 56 (2018) 41–46. doi:10.1016/J.PARKRELDIS.2018.06.016.
- [44] L.-J. Ma, L.-L. Xu, C. Mao, Y.-T. Fu, X.-Y. Ji, Y. Shen, J. Chen, Y. Yang, C.-F. Liu, Progressive Changes in the Retinal Structure of Patients with Parkinson's Disease, *J. Park. Dis.* 8 (2018) 85–92. doi:10.3233/JPD-171184.
- [45] M.M. Moschos, I.P. Chatziralli, Evaluation of Choroidal and Retinal Thickness Changes in Parkinson's Disease Using Spectral Domain Optical Coherence Tomography, *Semin. Ophthalmol.* 33 (2018) 494–497. doi:10.1080/08820538.2017.1307423.
- [46] M. Unlu, D. Gulmez Sevim, M. Gultekin, C. Karaca, Correlations among multifocal electroretinography and optical coherence tomography findings in patients with Parkinson's disease, *Neurol. Sci.* 39 (2018) 533–541. doi:10.1007/S10072-018-3244-2.
- [47] T.S. Aydin, D. Umit, O.M. Nur, U. Fatih, K. Asena, O.Y. Nefise, Y. Serpil, Optical coherence tomography findings in Parkinson's disease, *Kaohsiung J. Med. Sci.* 34 (2018)

- 166–171. doi:10.1016/J.KJMS.2017.11.006.
- [48] J. Doustar, T. Torbati, K.L. Black, Y. Koronyo, M. Koronyo-Hamaoui, Optical Coherence Tomography in Alzheimer's Disease and Other Neurodegenerative Diseases, *Front. Neurol.* 8 (2017). doi:10.3389/FNEUR.2017.00701.
- [49] M. Satue, J. Obis, M.J. Rodrigo, S. Otin, M.I. Fuertes, E. Vilades, H. Gracia, J.R. Ara, R. Alarcia, V. Polo, J.M. Larrosa, L.E. Pablo, E. Garcia-Martin, Optical Coherence Tomography as a Biomarker for Diagnosis, Progression, and Prognosis of Neurodegenerative Diseases, *J. Ophthalmol.* 2016 (2016) 1–9. doi:10.1155/2016/8503859.
- [50] D. Huang, E. Swanson, C. Lin, J. Schuman, W. Stinson, W. Chang, M. Hee, T. Flotte, K. Gregory, C. Puliafito, al. et, Optical coherence tomography, *Science.* 254 (1991) 1178–1181. doi:10.1126/SCIENCE.1957169.
- [51] J.F. de Boer, B. Cense, B.H. Park, M.C. Pierce, G.J. Tearney, B.E. Bouma, Improved signal-to-noise ratio in spectral-domain compared with time-domain optical coherence tomography, *Opt. Lett.* 28 (2003) 2067. doi:10.1364/OL.28.002067.
- [52] M. Choma, M. Sarunic, C. Yang, J. Izatt, Sensitivity advantage of swept source and Fourier domain optical coherence tomography, *Opt. Express.* 11 (2003) 2183. doi:10.1364/OE.11.002183.
- [53] J. Yu, Y. Feng, Y. Xiang, J. Huang, G. Savini, V. Parisi, W. Yang, X. Fu, Retinal Nerve Fiber Layer Thickness Changes in Parkinson Disease: A Meta-Analysis, *PLoS ONE.* 9 (2014) e85718. doi:10.1371/JOURNAL.PONE.0085718.
- [54] D. Moher, A. Liberati, J. Tetzlaff, D.G. Altman, for the PRISMA Group, Preferred reporting items for systematic reviews and meta-analyses: the PRISMA statement, *BMJ.* 339 (2009) b2535–b2535. doi:10.1136/BMJ.B2535.
- [55] J. Fujimoto, E. Swanson, The Development, Commercialization, and Impact of Optical Coherence Tomography, *Investig. Ophthalmology Vis. Sci.* 57 (2016) OCT1. doi:10.1167/IOVS.16-19963.
- [56] R. Suurmond, H. van Rhee, T. Hak, Introduction, comparison, and validation of Meta-Essentials : A free and simple tool for meta-analysis, *Res. Synth. Methods.* 8 (2017) 537–553. doi:10.1002/JRSM.1260.
- [57] National Eye Institute. Early Treatment Diabetic Retinopathy Study Research Group., Early treatment diabetic retinopathy study (ETDRS) : manual of operations, U.S. Dept. of

- Commerce, National Technical Information Service, [Springfield, Va.], 1985.
- [58] Ö. Altıntaş, P. Işeri, B. Özkan, Y. Çağlar, Correlation between retinal morphological and functional findings and clinical severity in Parkinson's disease, *Doc. Ophthalmol.* 116 (2008) 137–146. doi:10.1007/S10633-007-9091-8.
- [59] M.M. Moschos, G. Tagaris, L. Markopoulos, L. Margetis, S. Tsapakis, M. Kanakis, C. Koutsandrea, Morphologic Changes and Functional Retinal Impairment in Patients with Parkinson Disease without Visual Loss, *Eur. J. Ophthalmol.* 21 (2011) 24–29. doi:10.5301/EJO.2010.1318.
- [60] N.K. Archibald, M.P. Clarke, U.P. Mosimann, D.J. Burn, Retinal thickness in Parkinson's disease, *Parkinsonism Relat. Disord.* 17 (2011) 431–436. doi:10.1016/j.parkreldis.2011.03.004.
- [61] E.E. Tsironi, A. Dastiridou, A. Katsanos, E. Dardiotis, S. Veliki, G. Patramani, F. Zacharaki, S. Ralli, G.M. Hadjigeorgiou, Perimetric and retinal nerve fiber layer findings in patients with Parkinson's disease, *BMC Ophthalmol.* 12 (2012). doi:10.1186/1471-2415-12-54.
- [62] C. La Morgia, P. Barboni, G. Rizzo, M. Carbonelli, G. Savini, C. Scaglione, S. Capellari, S. Bonazza, M.P. Giannoccaro, G. Calandra-Buonaura, R. Liguori, P. Cortelli, P. Martinelli, A. Baruzzi, V. Carelli, Loss of temporal retinal nerve fibers in Parkinson disease: a mitochondrial pattern?: Loss of temporal retinal nerve fibers in PD, *Eur. J. Neurol.* 20 (2013) 198–201. doi:10.1111/j.1468-1331.2012.03701.x.
- [63] A.U. Bayer, O.N. Keller, F. Ferrari, K.-P. Maag, Association of glaucoma with neurodegenerative diseases with apoptotic cell death: Alzheimer's disease and Parkinson's disease, *Am. J. Ophthalmol.* 133 (2002) 135–137. doi:10.1016/S0002-9394(01)01196-5.
- [64] S.J. McKinnon, The Cell and Molecular Biology of Glaucoma: Common Neurodegenerative Pathways and Relevance to Glaucoma, *Investig. Ophthalmology Vis. Sci.* 53 (2012) 2485. doi:10.1167/IOVS.12-9483J.
- [65] A.I. Ramirez, R. de Hoz, E. Salobrar-Garcia, J.J. Salazar, B. Rojas, D. Ajoy, I. López-Cuenca, P. Rojas, A. Triviño, J.M. Ramírez, The Role of Microglia in Retinal Neurodegeneration: Alzheimer's Disease, Parkinson, and Glaucoma, *Front. Aging Neurosci.* 9 (2017). doi:10.3389/FNAGI.2017.00214.
- [66] S.-W. Lai, C.-L. Lin, K.-F. Liao, Glaucoma correlates with increased risk of Parkinson's

- disease in the elderly: a national-based cohort study in Taiwan, *Curr. Med. Res. Opin.* 33 (2017) 1511–1516. doi:10.1080/03007995.2017.1322570.
- [67] C. La Morgia, L. Di Vito, V. Carelli, M. Carbonelli, Patterns of Retinal Ganglion Cell Damage in Neurodegenerative Disorders: Parvocellular vs Magnocellular Degeneration in Optical Coherence Tomography Studies, *Front. Neurol.* 8 (2017). doi:10.3389/fneur.2017.00710.
- [68] L. Guo, E.M. Normando, P.A. Shah, L. De Groef, M.F. Cordeiro, Oculo-visual abnormalities in Parkinson's disease: Possible value as biomarkers: Ocular Markers in PD, *Mov. Disord.* 33 (2018) 1390–1406. doi:10.1002/mds.27454.
- [69] V. Kansal, J.J. Armstrong, R. Pintwala, C. Hutnik, Optical coherence tomography for glaucoma diagnosis: An evidence based meta-analysis, *PLOS ONE.* 13 (2018) e0190621. doi:10.1371/JOURNAL.PONE.0190621.
- [70] J. den Haan, F.D. Verbraak, P.J. Visser, F.H. Bouwman, Retinal thickness in Alzheimer's disease: A systematic review and meta-analysis, *Alzheimers Dement. Diagn. Assess. Dis. Monit.* 6 (2017) 162–170. doi:10.1016/J.DADM.2016.12.014.
- [71] K. Safranow, Ophthalmological Features of Parkinson Disease, *Med. Sci. Monit.* 20 (2014) 2243–2249. doi:10.12659/MSM.890861.

**Legend**

Figure 1. PRISMA chart showing the study selection and inclusion process [54].

Figure 2. Thickness of the peripapillary retinal nerve fiber layer in Parkinson's patients versus controls. Cohen's d effect sizes per study and from meta-analysis.

Figure 3. Thickness of the retinal ganglion cell layer and inner plexiform layer in Parkinson's patients versus controls. Cohen's d effect sizes per study and from meta-analysis.

Figure 4. Overall retinal thickness in the macular area of Parkinson's patients versus healthy controls, depicted as Cohen's d effect sizes from the meta-analyses summarizing the various regions of interest.

Figure 5. Thickness of the peripapillary retinal nerve fiber layer in Parkinson's patients versus healthy controls, depicted as Cohen's d effect sizes from the meta-analyses summarizing the four sectors.

Table 1

Study	Author	Year	OCT	N		Age (SD)		% male		Disease duration (years)	UPDRS III	UPDRS total	HY	MMSE	Medication
				PD	Control	PD	Control	PD	Control						
1	Mohammedyusuf E. Hajee	2009	RTVue	24	17	64 (6.5)	63.5 (10.7)	-	-	2.9	-	-	-	-	-
2	Elena Garcia-Martin	2012	Spectralis	75	75	64.4	64.2	66	65.6	7.5	-	-	-	28.9 (8.3)	-
3	Philipp Albrecht	2012	Spectralis	40	35	61.2 (2)	-	-	-	8.1	36.4 (23.8)	-	2.5 (0.2)	-	OFF
4	M Satue	2013	Spectralis	100	100	64	64	-	-	5.3	-	-	2.73	-	-
5	Mohammad Rohani	2013	3D-OCT	27	25	54.5 (10.4)	55 (8)	74.1	68	5.6	-	-	-	-	-
6	Serkan Kirbas	2013	Cirrus	42	40	59.3 (4.9)	57 (4.9)	47	62	-	-	-	-	-	-
7	Aysu Sen	2014	RTVue	35	11	62.4 (8)	61.18 (8)	43	45.5	3	-	-	-	-	-
8	Elena Garcia-Martin	2014	Spectralis	129	129	68.7	69	55.8	55.8	8.4	-	-	2.7	-	-
9	Elena Garcia-Martin	2014	Spectralis	46	33	70.7	69.6	63	64	7.7	-	-	2.2 (0.8)	-	-
10a	Elena Garcia-Martin	2014	Spectralis	111	200	65.4	65.3	63.3	63	7.6	-	-	-	-	-
10b	Elena Garcia-Martin	2014	Spectralis	60	120	65.1	65.3	63.3	63	7.6	-	-	-	-	-
11	Esin S. Sari	2014	Cirrus	54	54	66.6 (8.7)	66.6 (7.9)	55.6	51.9	5.1	-	-	2.26 (0.9)	-	-
12	Hasan Ali Bayhan	2014	RTVue	20	30	65.6 (7.1)	63.5 (5.5)	55	56.7	2.2	13.9 (5.6)	27.3 (11.9)	1.7(0.9)	-	-
13	Jee-Young Lee	2014	Opko	56	30	69.6 (7.1)	64.8 (7.4)	39.3	46.7	-	26.4 (13.5)	52.2 (24.6)	2.2 (0.8)	24.1 (4.5)	-
14	Lucas Barasnevicius Quagliato	2014	RTVue	43	38	68.5 (7.6)	66.2 (8.9)	62.8	46.2	7	-	17.6 (8.9)	1.63	-	OFF
15	M Satue	2014	Spectralis	153	242	68	66	-	-	5.3	-	25	2.5	-	-
16	Max Schneider	2014	Cirrus	65	41	66.2 (12)	65.1 (9.4)	60	53.7	8.9	29 (16.5)	-	-	-	OFF
17	Nicolas M. Roth	2014	Cirrus	68	32	68.8 (8.1)	64.7 (7.5)	54.4	62.5	7.2	19 (10)	-	-	-	-
18	Birthe Stemplewitz	2015	Cirrus	108	165	64.3 (12.3)	56.9 (13)	63.9	42.4	6.2	-	-	2.1 (0.7)	-	-
19	Diana Bittersohl	2015	Spectralis	109	82	64.3 (10.2)	56.9 (13)	-	-	6.2	-	-	-	-	-
20	Manpreet Kaur	2015	Cirrus	20	20	58.6 (9.5)	58.4 (9.3)	-	-	5.8	19 (10.4)	-	2	-	-
21	Pooja Mailankody	2015	Spectralis	30	30	53.4 (10.6)	53.5 (10.6)	73.3	73.3	5.3	-	30.5 (14.8)	1.73 (0.5)	29.3 (2.1)	OFF
22	Anastasia Pilat	2016	Copernicus	25	25	60.7	60.5	76	76	6	-	-	-	-	-
23	Jagan A. Pillai	2016	Cirrus	20	34	62.6 (9.5)	65.1 (8.3)	55	41	-	23 (10.6)	-	-	-	OFF
24	Muhsin Eraslan	2016	RTVue	25	23	58.6 (10.3)	56.6 (9.6)	64	65.3	5.7	-	34.4 (16.2)	-	-	-
25	Turgay Ucak	2016	Cirrus	30	30	68.5 (7.6)	66.2 (8.9)	63.3	53.3	4.9	15.2 (4.1)	42.2 (15.6)	-	24.7 (4.5)	-
26	V Polo	2016	Cirrus	37	37	69	68	62.2	64.9	13.2	25 (8.2)	-	2.7 (0.6)	-	-
27	Maria Satue	2017	Spectralis	30	30	69.5 (6.6)	68.3 (8.5)	56.7	56.7	13.5	-	-	2.7 (0.7)	-	-
28	Duygu Gulmez Sevim	2018	Spectralis	29	33	57.3 (9.9)	58.9 (7.8)	55.2	55.6	5.3	-	-	-	-	-

29	Duygu Gulmez Sevim	2018	Spectralis	41	35	59.6 (9.9)	59.4 (7.6)	51	54	4	-	-	-	-	-
30	Femke Visser	2018	Spectralis	20	20	65	63	75	45	8	24	-	2	29	-
31	Jiang Huang	2018	Cirrus	53	41	61.8 (9.9)	62.3 (9.7)	58	66	5.6	37.1 (16.6)	-	1.9 (0.5)	-	-
32	Juliane Matlach	2018	Cirrus	40	23	64.1 (8.3)	64.1 (8.2)	70	46	9.8	-	-	-	-	-
33	Li-Jing Ma	2018	Cirrus	37	42	60.4 (8.4)	57.3 (9.5)	57	54	2.9	21.4 (11.5)	33.8 (15.2)	1.5	-	OFF
34	Marilita M. Moschos	2018	Spectralis	31	25	67.8 (3.9)	68 (4.1)	53.1	56	-	-	-	-	-	-
35	Metin Unlu	2018	Spectralis	58	30	59.7 (9.6)	60.2 (13.4)	53.5	50	8.4 (2.7)	-	-	-	-	-
36	Turkoglu Sule Aydin	2018	Spectralis	25	29	70	68	68	65.5	4	-	24	1	28	-
				1916	2006										

PD = Parkinson's disease patients; C = controls; SD = standard deviation.

Table 2

Study	PD patients (mean [SD])	Controls (mean [SD])	Difference	Cohen's d (CI 95%)	Weight
Table 2a					
pRNFL ( $\mu\text{m}$ )					
2	97.2 (5.2)	101.5 (5.2)	-4.4	-0.84 (-1.18, -0.51)	3.6%
3	97.3 (10.2)	99.1 (9.4)	-1.8	-0.18 (-0.64, 0.27)	2.9%
4	98.7 (12)	101.9 (8.7)	-3.2	-0.30 (-0.58, -0.03)	3.9%
5	91.2 (10.5)	102.6 (13.5)	-11.4	-0.93 (-1.53, -0.37)	2.3%
6	77 (11.6)	89 (8.7)	-12	-1.16 (-1.64, -0.70)	2.8%
7	105.7 (9.5)	115.6 (9.1)	-9.9	-1.04 (-1.77, -0.34)	1.8%
8	98.4 (10.2)	100.8 (9.1)	-2.4	-0.24 (-0.49, 0)	4.1%
9	97.8 (8.4)	99.4 (10.1)	-1.6	-0.17 (-0.62, 0.28)	2.9%
10a	97.5 (14.5)	101.2 (9.1)	-3.6	-0.32 (-0.55, -0.09)	4.2%
10b	94.2 (17.1)	101.4 (8.4)	-7.2	-0.60 (-0.92, -0.28)	3.7%
11	89.7 (12)	93 (9.3)	-3.3	-0.30 (-0.69, 0.07)	3.3%
12	104.4 (13.3)	110.6 (12.2)	-6.2	-0.48 (-1.07, 0.09)	2.3%
14	103.1 (12)	105.9 (12.8)	-2.8	-0.22 (-0.66, 0.22)	3.0%
15	97.6 (11)	103.2 (11.3)	-5.7	-0.50 (-0.71, -0.30)	4.4%
17	92.6 (8.8)	91.5 (10.7)	1.1	0.12 (-0.31, 0.54)	3.1%
18	91.2 (6.2)	91.6 (7.7)	-0.4	-0.06 (-0.30, 0.19)	4.2%
19	95.7 (9.4)	96.1 (7.2)	-0.4	-0.05 (-0.33, 0.24)	3.9%
20	85.4 (12.4)	91.1 (8)	-5.7	-0.54 (-1.19, 0.09)	2.1%
21	97.9 (11.9)	99.1 (10.7)	-1.2	-0.10 (-0.62, 0.40)	2.6%
22	96.9 (11.9)	109.3 (18.1)	-12.4	-0.8 (-1.39, -0.23)	2.3%
23	88.5 (9.4)	85.3 (9.3)	3.2	0.34 (-0.22, 0.90)	2.4%
24	105.4 (13.5)	113.8 (8.5)	-8.3	-0.72 (-1.32, -0.14)	2.3%
25	89.4 (7.5)	94.6 (8.1)	-5.3	-0.66 (-1.2, -0.15)	2.6%
26	94.9 (11.5)	96.2 (6.7)	-1.3	-0.14 (-0.6, 0.32)	2.9%
27	96.4 (9.5)	98.2 (9.1)	-1.8	-0.19 (-0.7, 0.32)	2.6%
28	98 (8)	97.9 (11.7)	0.1	0.01 (-0.50, 0.51)	2.7%
29	89.5 (8.7)	98.7 (11.3)	-9.2	-0.91 (-1.40, -0.44)	2.8%
30	91 (10)	92 (18)	-1	-0.07 (-0.70, 0.56)	2.1%
31	88.9 (18.8)	92.7 (11.5)	-3.8	-0.23 (-0.65, 0.17)	3.1%
32	88.5 (12.3)	93.6 (8.8)	-5.1	-0.45 (-0.98, 0.07)	2.6%
33	94.7 (7.3)	102.7 (5.1)	-8	-1.27 (-1.77, -0.80)	2.7%
34	95.1 (11.9)	103.9 (3.9)	-8.8	-0.94 (-1.51, -0.39)	2.4%
35	97.5 (8.6)	100 (10)	-2.5	-0.27 (-0.72, 0.17)	3.0%
36	97.1 (12.8)	104 (7.1)	-6.9	-0.67 (-1.24, -0.13)	2.4%
Overall Effect	94.8	99.3	-4.2	-0.42 (-0.54, -0.29)	

Table 2b

GCL-IPL ( $\mu\text{m}$ )					
3	99.8 (8.1)	98.7 (9.5)	1.1	0.12 (-0.33, 0.58)	9.4%
11	68.6 (16.3)	81.3 (6.3)	-12.7	-1.02 (-1.43, -0.62)	9.9%
13	70.2 (17.6)	79.8 (15.8)	-9.6	-0.56 (-1.02, -0.11)	9.4%
16	71.7 (8)	72.4 (6.7)	-0.7	-0.09 (-0.49, 0.3)	10%
17	78.1 (8)	79.2 (7.4)	-1.1	-0.14 (-0.56, 0.28)	9.7%
20	71.5 (15.8)	81.5 (5.3)	-10	-0.83 (-1.50, -0.19)	7.6%
22	82.7 (8.9)	83.7 (7.1)	-1	-0.12 (-0.68, 0.44)	8.4%
23	77.5 (14.2)	73.5 (11.3)	4	0.32 (-0.24, 0.88)	8.4%
25	78 (8.1)	81 (6.3)	-3	-0.40 (-0.92, 0.11)	8.8%



26	82.7 (6.2)	84.8 (4.1)	-2.1	-0.39 (-0.86, 0.06)	9.3%
35	78.6 (3.4)	82.6 (2.5)	-4	-1.26 (-1.75, -0.79)	9.1%
Overall Effect	78.1	81.7	-3.6	-0.40 (-0.72, -0.07)	

Table 2c

INL ( $\mu\text{m}$ )					
3	46.8 (5.9)	42.8 (4.1)	4	0.77 (0.31, 1.26)	19.9%
13	30.7 (6.3)	35.2 (7.5)	-4.4	-0.65 (-1.11, -0.20)	20.1%
16	36 (3.2)	37.2 (2.9)	-1.2	-0.39 (-0.78, 0.01)	21%
22	36.8 (5.6)	35.4 (5.8)	1.4	0.24 (-0.32, 0.80)	18.6%
35	36.6 (2.9)	36.9 (3.9)	-0.3	-0.03 (-0.72, 0.66)	20.3%
Overall Effect	37.4	37.5	-0.1	-0.01 (-1.03, 1.01)	

Table 2d

OPL ( $\mu\text{m}$ )					
3	33.7 (4.6)	34.6 (6.1)	-0.9	-0.16 (-0.62, 0.30)	20%
13	32.1 (7.9)	29.7 (5.1)	2.5	0.34 (-0.10, 0.80)	20.4%
16	24.5 (5.1)	25 (3.5)	-0.5	-0.11 (-0.50, 0.28)	23.7%
22	28.6 (5.5)	28.6 (5.5)	0	0 (-0.56, 0.56)	15.5%
35	30.7 (3)	29.3 (2.7)	1.4	0.48 (0.03, 0.93)	20.4%
Overall Effect	30	29.4	0.5	0.11 (-0.25, 0.47)	

Table 2e

ONL ( $\mu\text{m}$ )					
16	121.2 (9.6)	124.1 (10.2)		-2.9	
35	59.6 (8.3)	68.8 (15.4)		-9.2	
ORL ( $\mu\text{m}$ )					
1	169.1 (7.7)	169.2 (23.3)		-0.1	
IRL ( $\mu\text{m}$ )					
1	89.3 (11.2)	103.7 (23.9)		-14.4	
RPE ( $\mu\text{m}$ )					
35	13.7 (1.3)	15.1 (2.1)		-1.4	

pRNFL = peripapillary retinal nerve fiber layer; GCL-IPL = ganglion cell complex-inner plexiform layer; INL = inner nuclear layer; OPL = outer plexiform layer; ONL = outer nuclear layer; ORLs = outer retinal layer; IRLs = inner retinal layer, RPE= retinal pigment epithelium.

Table 3

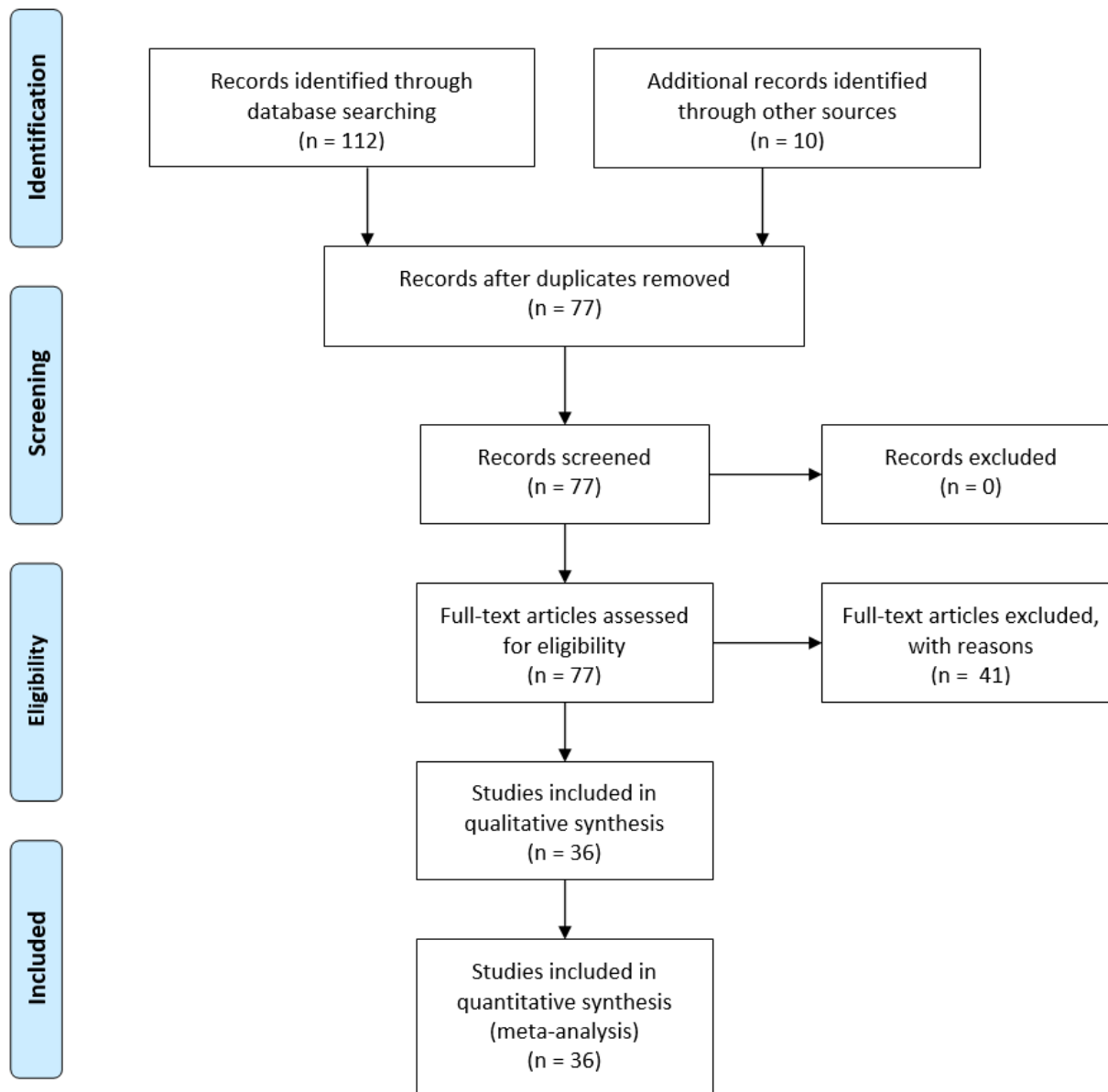
	Macula ( $\mu\text{m}$ )		Weighted Mean	Weighted average	N		I <sup>2</sup>
	PD (SD)	Control (SD)	Difference	Cohen's d (CI 95%)	PD	Control	
Fovea	271.2 (24.2)	274.3 (20.3)	-2.8	-0.12 (0.02, -0.26)	702	874	18.4%
Inferior inner	324.2 (20.5)	331.6 (17)	-7.7	-0.43 (-0.10, -0.76)	702	874	85.9%
Inferior outer	277.3 (19.5)	286.6 (16.8)	-9.4	-0.50 (-0.07, -0.93)	702	874	92%
Nasal inner	329 (19.8)	335.3 (18.1)	-6.8	-0.37 (-0.14, -0.59)	702	874	72.1%
Nasal outer	299.9 (20.4)	307.5 (17.7)	-8	-0.43 (-0.19, -0.66)	702	874	75%
Superior inner	327.8 (20.4)	334.7 (17)	-7.4	-0.43 (-0.14, -0.72)	702	874	80.8%
Superior outer	286.8 (17.6)	296.1 (15.8)	-9.5	-0.57 (-0.17, -0.98)	702	874	91.3%
Temporal inner	316.1 (20.2)	323.4 (16.8)	-7.7	-0.45 (-0.21, -0.69)	702	874	73.8%
Temporal outer	272.4 (19.3)	278.6 (17.1)	-6.6	-0.39 (-0.17, -0.61)	702	874	70.1%

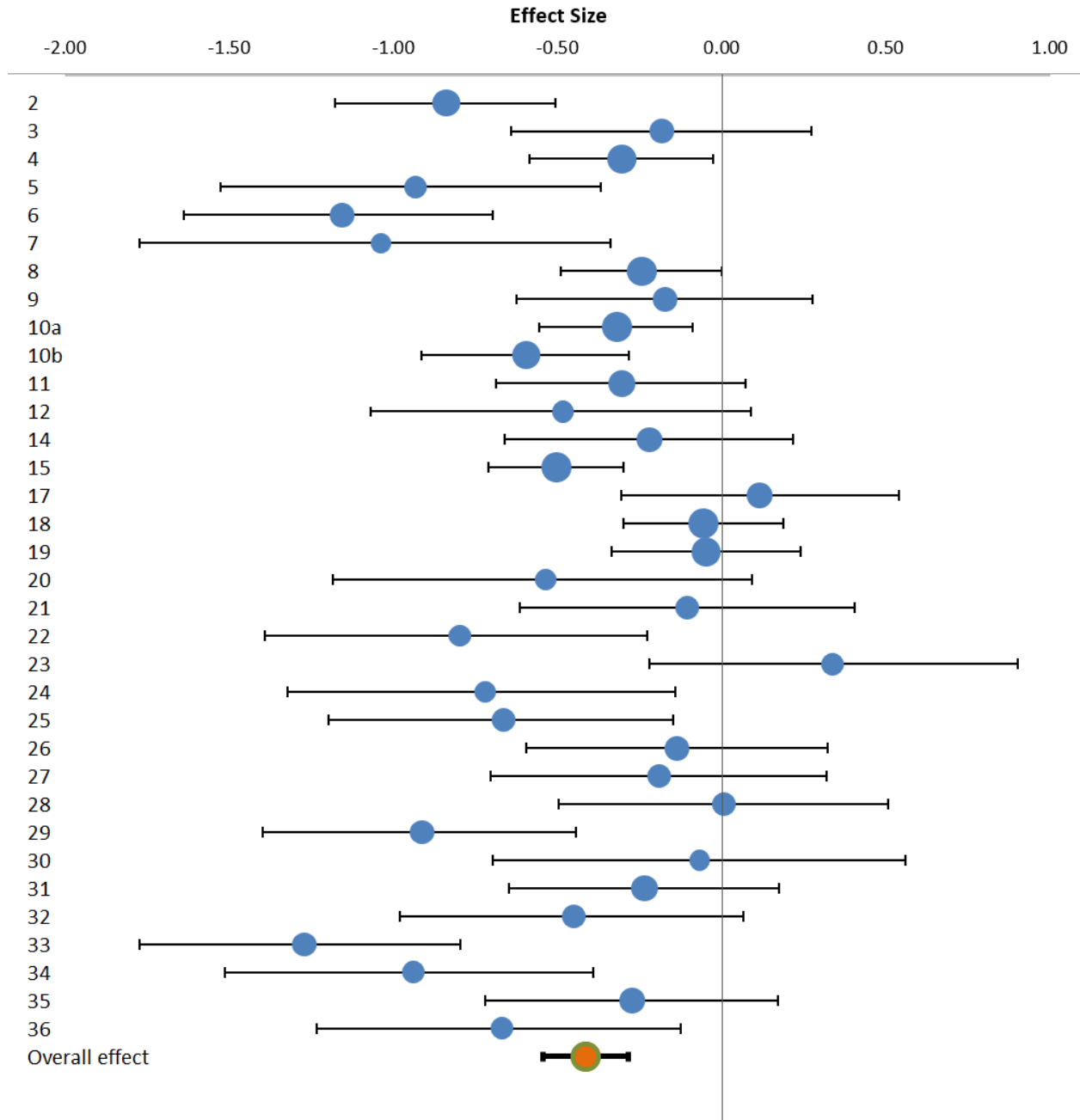
papers: 4, 9, 10a, 10b, 13, 15, 19, 26, 27

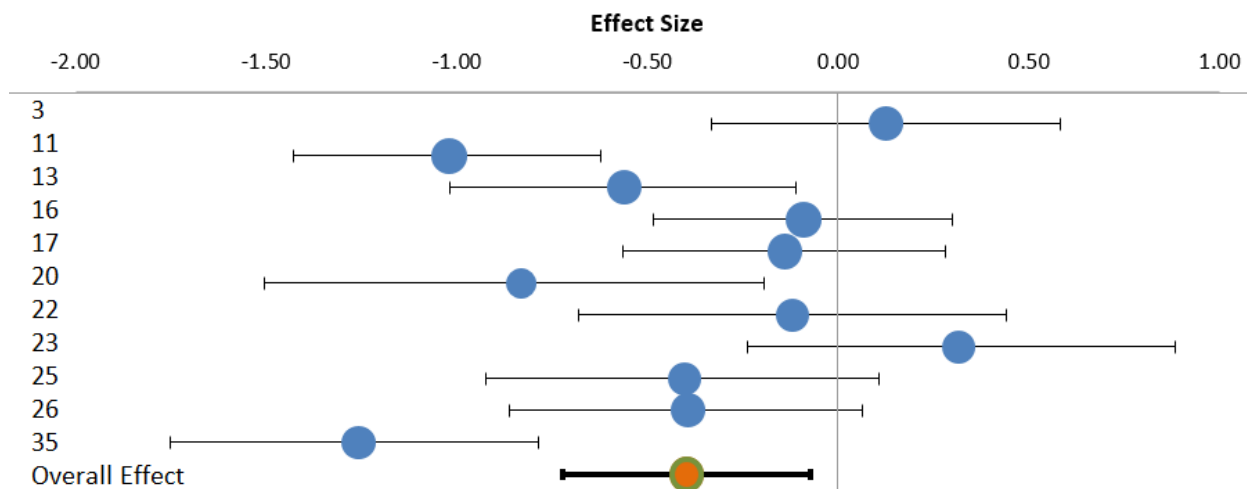
Table 4

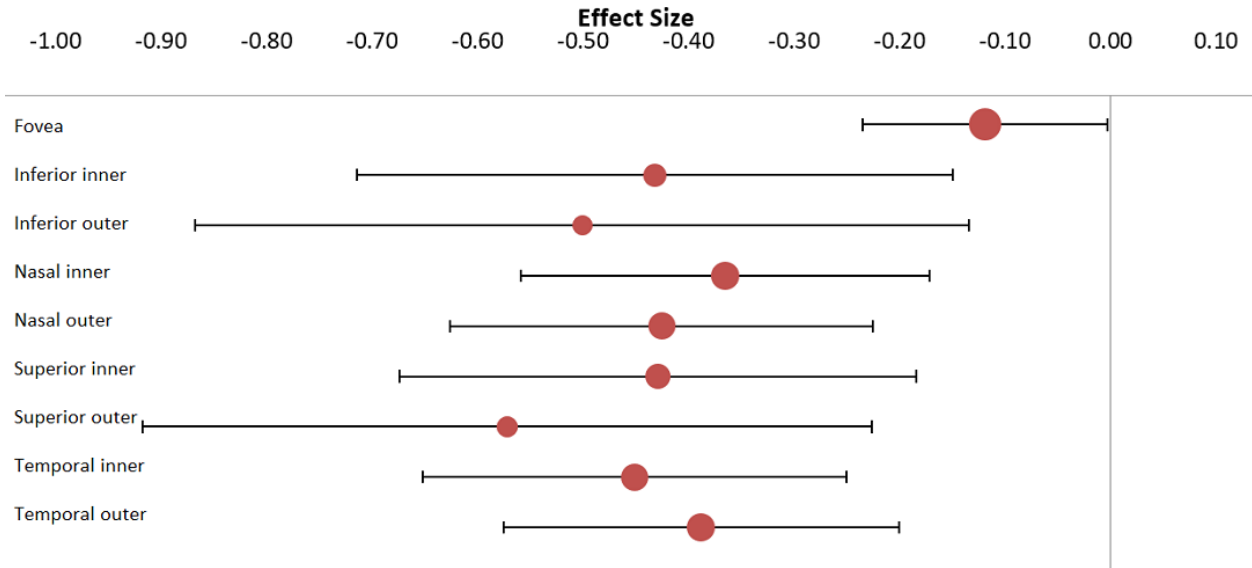
pRNFL sectors ( $\mu\text{m}$ )	Weighted Mean		Weighted average	N		I <sup>2</sup>	
	PD (SD)	Control (SD)	Cohen's d (CI 95%)	PD	Control		
Inferior	120.3 (19.8)	125.6 (17.3)	-6	-0.33 (-0.20, -0.45)	651	716	59.7%
Nasal	71.7 (14.3)	73.2 (12.9)	-1.7	-0.14 (0.05, -0.32)	651	716	53%
Superior	116.2 (16.9)	119.8 (15.1)	-4.2	-0.26 (-0.12, -0.40)	651	716	51.4%
Temporal	66.7 (13)	70.6 (11.6)	-3.7	-0.30 (-0.19, -0.40)	651	716	0%

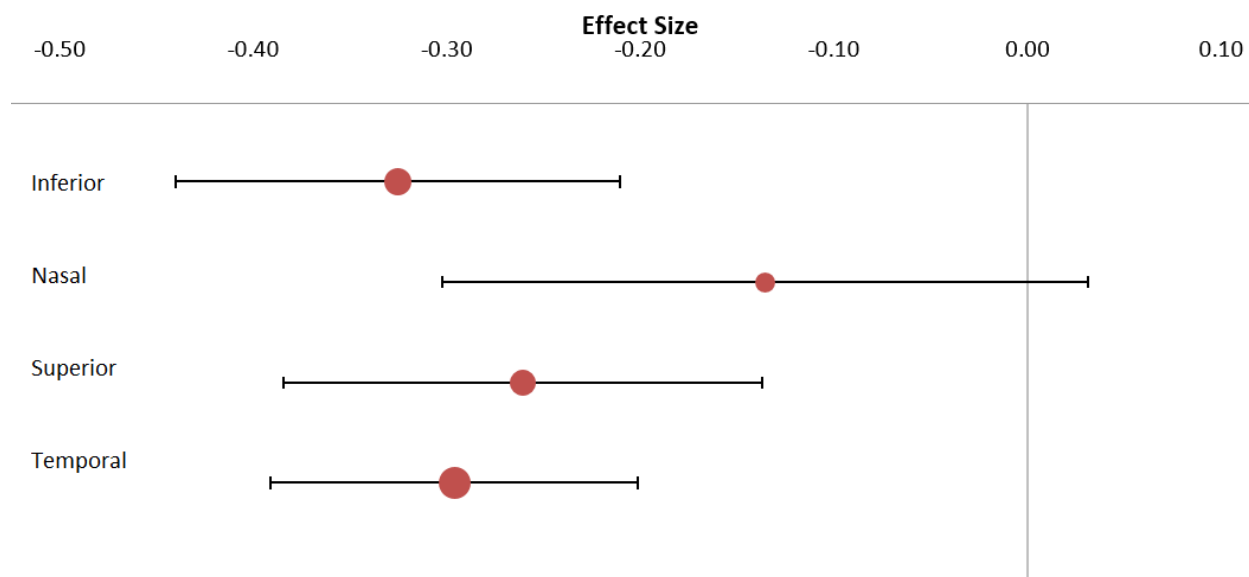
papers: 3, 4, 9, 11, 12, 15, 23, 26, 30, 31, 32, 33, 34.











ACCEPTED MANUSCRIPT



- Retinal cell layers are thinner in Parkinson's compared to healthy controls, overall.
- The retinal nerve fiber layer, ganglion cells and inner plexiform layer are thinner.
- The inner nuclear layer and outer plexiform layer showed no difference.
- The peripapillary nasal sector appears to be less affected compared to other sectors.
- The macula is thinner, however the fovea appears to be less affected.